

# HALLUX VALGUS: COMPARATIVE STUDY BETWEEN TWO SURGICAL TECHNIQUES OF PROXIMAL ADDITION OSTEOTOMY

LUIZ CARLOS RIBEIRO LARA, BRUNO VIerno DE ARAUJO, NELSON FRANCO FILHO, ROBERTO MINORU HITA

## ABSTRACT

**Objective:** Compare clinically and radiographically the results of the treatment of the hallux valgus, by two techniques of addition osteotomies: one using the resected exostosis, and the other using a plate. **Methods:** We evaluated 24 feet of 19 patients, mean age 51,3, affected by hallux valgus, with a mean follow-up of 50,1 months. 13 feet underwent to addition osteotomy resected exostosis (AORE) and to addition osteotomy with plate (AOP) 11 patients (11 feet). The values measured before and after the surgeries are given for AOFAS score, intermetatarsal 1 and 2, and hallux valgus angle. **Results:** In the feet underwent AORE,

the mean preoperative AOFAS was 46,6, IMA 14° and HVA 32°, while at the follow-up it was AOFAS 81,3, IMA 9° and HVA 25° with 92,3% of satisfactory results. The feet underwent AOP, the mean preoperative AOFAS was 42,1, IMA 15° and HVA 29° while at the follow-up it was AOFAS 77,4, IMA 11° and HVA 23° with 81,8% of satisfactory results. **Conclusion:** Both techniques proved to be efficient to the treatment of hallux valgus, clinically and radiographically, with no statistical difference between them. **Level of evidence III, Retrospective comparative study.**

**Keywords:** Hallux valgus. Osteotomy. Bone plate.

**Citation:** Lara LCR, Franco Filho N, Hita RM, Araujo BV. Hallux Valgus: Comparative study between two surgical techniques of proximal addition osteotomy. *Acta Ortop Bras.* [online]. 2012;20(6):351-5. Available from URL: <http://www.scielo.br/oaob>.

## INTRODUCTION

Hallux valgus is the main pathology of the forefoot, affecting the first metatarsophalangeal joint. It is defined as lateral deviation of the hallux associated with varus deformity of the first metatarsal, producing a medial bone prominence at the level of the first metatarsophalangeal joint.<sup>1-3</sup>

The genesis of this deformity is made up of extrinsic and intrinsic factors. An extrinsic factor that stands out is the use of footwear with triangular toe box and high heel that leads to the approximation of the metatarsal heads, producing lateral deviation of the hallux. Special emphasis is placed on the following intrinsic factors: heredity, varus deformity of the first metatarsal, ligament laxity, variations of length of the first metatarsal, format of the first tarsometatarsal joint and fallen arches.<sup>2,4,5</sup>

The conservative treatment is of a palliative nature, alleviating the symptoms but not correcting the deformities; accordingly, surgical treatment would be indicated in painful cases. There are descriptions of countless surgical techniques in literature, yet there is not a single surgical approach with satisfactory results for all cases, for which reason it falls to the orthopedist to indicate the best technique, according to the anatomical

variations, length of the first metatarsal, degrees of hallux valgus deformity, presence or absence of metatarsophalangeal joint arthrosis and first ray hypermobility.<sup>5,6-8</sup>

## OBJECTIVE

The aim of this study is to analyze and compare the outcome of the surgical treatment of symptomatic index-minus hallux valgus treated with the use of two addition osteotomy techniques. The first using resected exostosis of the distal epiphysis of the first metatarsal (addition osteotomy with resected exostosis - AORE) and the second, through fixation using an addition wedge plate (AOP).

## MATERIAL AND METHODS

During the period between June 1999 and April 2009, 19 patients (24 feet) with light and moderate index-minus hallux valgus were submitted to surgery. All the patients were treated at Hospital Universitário de Taubaté (HUT), at Fundação de Saúde Municipal de Caçapava (FUSAM) or at the private clinic of one of the authors. There was a predominance of female individuals (17 patients/22 feet) over male individuals (two patients/two feet). The average age at the time of surgery was 51.3 years with a minimum of

All the authors declare that there is no potential conflict of interest referring to this article.

Universidade de Taubaté - Department of Medicine - Taubaté, SP, Brazil.

Study conducted at Hospital Universitário de Taubaté (HUT) and at Fundação de Saúde Municipal de Caçapava (FUSAM). Mailing address: Rua Vereador Rafael Braga, 200 - Jardim Santa Clara, Taubaté - SP, Brazil. CEP 12080-080. Email: [brunovierno@yahoo.com.br](mailto:brunovierno@yahoo.com.br)

Article received on 9/15/2010 and approved on 4/12/2011.

Acta Ortop Bras. 2012;20(6): 351-5

17 years and maximum of 66 years. The most affected side was the left (14 feet) when compared to the right (10 feet). Five patients were operated bilaterally.

The AORE surgical technique was applied to 13 feet of 10 patients and the AOP technique was employed on 11 feet of 11 patients. Two patients with bilateral deformity were submitted to AOP in one foot and AORE in the other.

The minimum postoperative follow-up time in the general sample was six months, maximum of 144 months, averaging 50.1 months. In the group submitted to AORE the mean follow-up was 79.4 months with minimum of 12 months and maximum of 144 months. In the feet operated by AOP, the mean follow-up was 20.7 months, with minimum of six months and maximum of 31 months. Table 1 presents number of order, initials of the patients, age at surgery, sex, laterality, surgical technique employed and postoperative follow-up time.

**Table 1.** Identification of the studied cases.

Number	Age at surgery	Sex	Laterality	Surgical technique	Postoperative time
1	34y	F	L	OAE0	144m
2	58y	F	L	OAE0	124m
3	52y	F	R	OAE0	106m
4	52y	F	L	OAE0	106m
5	50y	F	R	OAE0	91m
6	50y	F	L	OAE0	91m
7	50y	F	R	OAE0	74m
8	65y	F	R	OAE0	71m
9	52y	F	L	OAE0	50m
10	39y	F	L	OAE0	41m
11	65y	F	L	OAE0	38m
12	58y	F	L	OPCA	31m
13	51y	F	R	OPCA	29m
14	54y	F	R	OPCA	27m
15	66y	F	R	OPCA	27m
16	17y	M	L	OAE0	26m
17	40y	F	R	OPCA	26m
18	57y	F	R	OPCA	24m
19	64y	F	L	OPCA	24m
20	62y	F	L	OPCA	14m
21	51y	F	L	OPCA	12m
22	36y	F	L	OAE0	12m
23	48y	F	L	OPCA	8m
24	62y	M	R	OPCA	6m

F - female; M - male; R - right; L - left; AORE - Additional osteotomy with resected exostosis; AOP - Osteotomy and addition wedge plate; y - years; m - months

\* - Patients operated using the two techniques.

Source - Hospital Universitário de Taubaté - Taubaté, SP - 2009.

## SURGICAL TECHNIQUES

### Addition osteotomy with bone graft taken from the exostosis (AORE)

After asepsis and antisepsis, with the limb bloodless, we made a longitudinal and medial incision starting two centimeters from the medial exostosis of the head of the first metatarsus, continuing distally up to the proximal third of the proximal phalanx. We made a Y-shaped incision in the metatarsophalangeal joint capsule, leaving a capsular flap adhered to the base of the proximal phalanx of the hallus, to assist us in the correction of the hallux valgus deformity when suturing it. We performed the exostectomy in the lengthwise direction with laminar chisel and hammer.

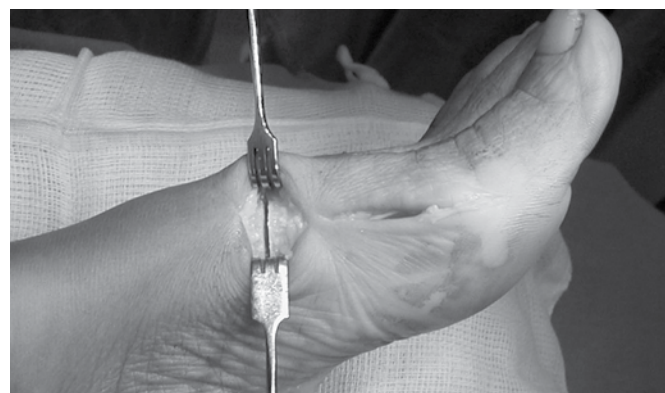
We made a second incision between the first and second metatarsal, measuring approximately two centimeters in length. Through this approach we sectioned the adductor hallucis ten-

don, an important factor to allow the correction of the sesamoids and the hallux valgus deformity. Finalizing, a last incision of three centimeters in the medial region of the foot, at the base of the first metatarsal, site of the osteotomy. Using a micro saw or chisel, one centimeter distal to the first metatarsal-cuneiform joint, we performed the base osteotomy at a right angle, preserving the integrity of the lateral cortex. (Figure 1)

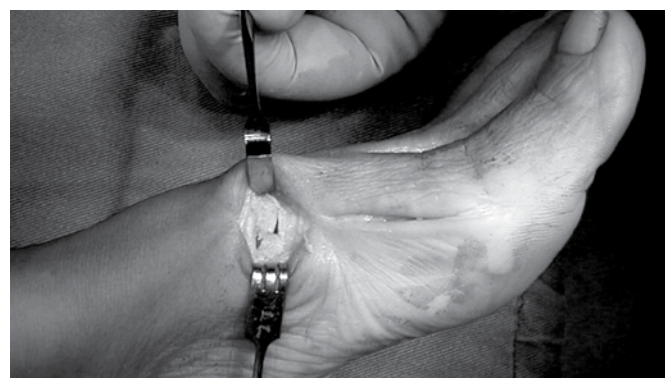We modeled the graft taken from the exostosis as an opening wedge of approximately 5mm then introduced it in the osteotomy, thus seeking to correct the varus deformity of the first metatarsal. (Figure 2)

We did not fix the majority of these osteotomies with synthesis, because the graft entered under pressure, opening the osteotomy and remaining firm, as the lateral cortex was preserved. We sutured the capsule (polyvicryl 0) with sufficient tension to aid in the correction of the hallux deformity. The limb was then immobilized with elastic compression bandage of the foot and of the ankle. Load bearing on the operated limb was disallowed for three weeks. In the following three weeks, walking was allowed with Barouk or postoperative stiff-soled sandals.

Osteotomy and fixation with addition wedge plate (AOP). Until the first metatarsal base osteotomy all the procedures carried out in the anterior technique were identical. The plate used was the L-shaped Low Profile Metatarsal Opening Wedge Plate from Arthrex, made of titanium, with four holes and a "step" for the osteotomy opening. The thickness of the "step", located in the lower portion of the plate, ranges from zero to seven millimeters, with the correction of approximately three degrees for each millimeter. (Figures 3, 4 and 5)



**Figure 1.** Proximal osteotomy. Exostectomy already executed.



**Figure 2.** Filling of wedge with the resected exostosis.



Figure 3. L-shaped Plate.

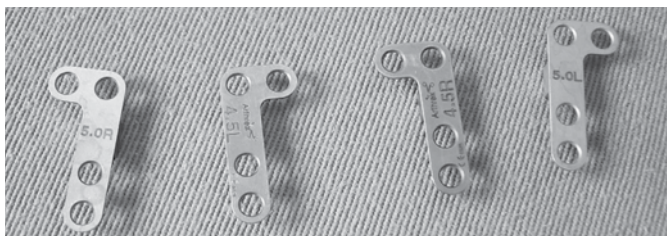

Figure 4. L-shaped Plate.

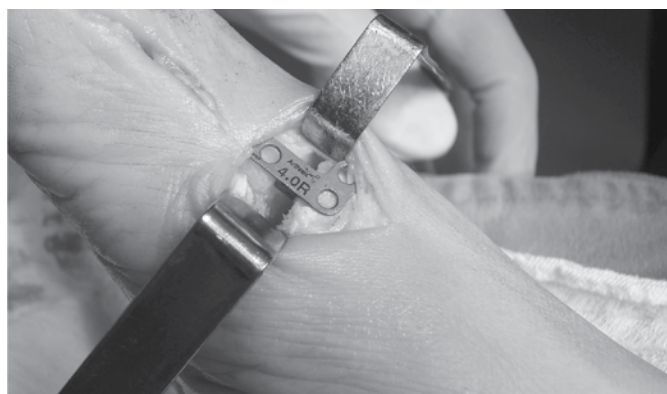

Figure 5. Placement of the plate.

From this point on the suturing and bandaging were identical to the AORE technique. We gave the patient the all clear to resume walking at an earlier stage, two weeks after surgery.

We performed a radiographic evaluation of HVA and IMA 1 and 2 in the anteroposterior view of the foot with the patient on the chassis in orthostatic position. These angles were measured in the preoperative and postoperative periods.

We applied the satisfaction scale questionnaire of the American Orthopaedics Foot and Ankle Society (AOFAS). (Appendix 1) This scale provides a score for eight factors, from zero to 100 points, related to hallux valgus, such as: pain, limitation of activity and of movement, type of footwear used, presence of calluses and first ray alignment. We consider values greater than or equal to 70 points satisfactory, and values below 70 points unsatisfactory. The statistical analysis was conducted through the Student's t-test for paired data with the objective of assessing the efficacy of the treatments. The significance level was set at 0.05.

To compare the AOFAS results and the measurements of the angles obtained in each technique employed we used the analysis of variance method and Turkey's test.

All the participating patients received an explanation about the study objectives and were asked to sign the informed consent form. This study was approved by the Ethics Committee of Universidade de Taubaté.

## RESULTS

With the AORE technique we obtained 92.3% satisfactory results (12 feet) and 7.7% unsatisfactory results (one foot). (Figure 6) In this group the mean AOFAS score in the preoperative period was 46.6 points, climbing to 81.3 in the postoperative period (SD 17.7 and 11.4). (Table 2)

The preoperative mean IMA and HVA were 14° and 32° (SD 2.0 and 1.7), dropping to 9° IMA and 25° HVA (SD 4.7 and 5.4), respectively, in the postoperative period. (Table 3)

The Student's t-test for paired data showed a significant improvement in the clinical (AOFAS) and radiographic aspects with this technique. ( $p < 0.05$ ).

In the group of feet submitted to the AOP technique, the percentage of satisfactory results was 81.8% (nine feet) while unsatisfactory results represented 18.2% (two feet). (Figure 7)

In these feet the mean AOFAS score in the preoperative period was 42.1 points, climbing to 77.4 points in the postoperative period (SD 14.8 and 16.1). (Table 4)

The preoperative mean IMA and HVA were 15° and 29° (SD 2.5 and 6.4), dropping to 11° IMA and 23° HVA (SD 4.0 and 10.4), respectively, in the postoperative period. (Table 5)

The Student's t-test for paired data showed a significant improvement in the clinical (AOFAS) and radiographic aspects with the use of AOP in this group of feet ( $p < 0.05$ ).

When compared by the analysis of variance and Turkey's test, both techniques exhibited similar results in the clinical (AOFAS) and radiographic aspects.

In the feet submitted to the AORE procedure we found 23% of complications: suture dehiscence, slow consolidation and

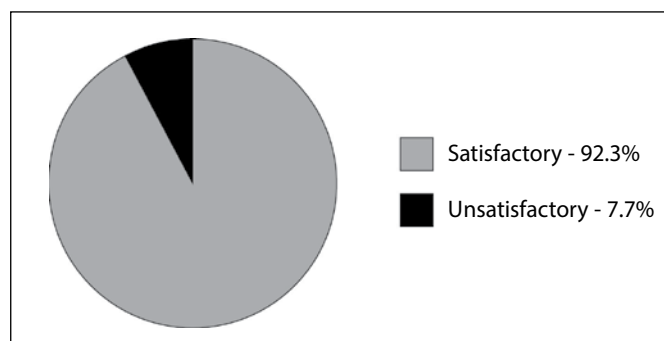


Figure 6. Percentage of satisfactory and unsatisfactory results in the feet submitted to AORE.

Table 2. AOFAS Score. Addition osteotomy with resected exostosis.

No. of order	Pre	Post
1	44	90
2	65	88
3	78	95
4	65	88
5	53	77
6	53	77
7	25	83
8	30	83
9	25	73
10	32	50
11	29	92
16	63	83
22	44	78
	Médias	
AOFAS	46.6	81.3

Source - Hospital Universitário de Taubaté - Taubaté, SP - 2009.



**Table 3.** Radiographic evaluation of the angles. Addition osteotomy with resected exostosis.

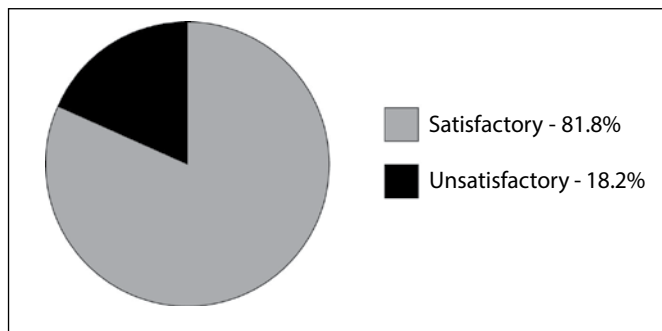
	Intermetatarsal		Metatarsophalangeal	
	Pre	Post	Pre	Post
1	15 <sup>th</sup>	8 <sup>th</sup>	36 <sup>th</sup>	20 <sup>th</sup>
2	13 <sup>th</sup>	9 <sup>th</sup>	28 <sup>th</sup>	18 <sup>th</sup>
3	15 <sup>th</sup>	6 <sup>th</sup>	34 <sup>th</sup>	21 <sup>st</sup>
4	14 <sup>th</sup>	8 <sup>th</sup>	35 <sup>th</sup>	28 <sup>th</sup>
5	15 <sup>th</sup>	12 <sup>th</sup>	32 <sup>nd</sup>	18 <sup>th</sup>
6	14 <sup>th</sup>	10 <sup>th</sup>	35 <sup>th</sup>	28 <sup>th</sup>
7	10 <sup>th</sup>	10 <sup>th</sup>	35 <sup>th</sup>	32 <sup>nd</sup>
8	13 <sup>th</sup>	11 <sup>th</sup>	31 <sup>st</sup>	21 <sup>st</sup>
9	15 <sup>th</sup>	11 <sup>th</sup>	38 <sup>th</sup>	31 <sup>st</sup>
10	12 <sup>th</sup>	-4 <sup>th</sup>	19 <sup>th</sup>	-18 <sup>th</sup>
11	19 <sup>th</sup>	12 <sup>th</sup>	33 <sup>rd</sup>	32 <sup>nd</sup>
16	14 <sup>th</sup>	9 <sup>th</sup>	32 <sup>nd</sup>	29 <sup>th</sup>
22	14 <sup>th</sup>	10 <sup>th</sup>	34 <sup>th</sup>	26 <sup>th</sup>
	Means			
	14 <sup>th</sup>	9 <sup>th</sup>	32 <sup>nd</sup>	25 <sup>th</sup>

Source - Hospital Universitário de Taubaté - Taubaté, SP – 2009.

**Table 5.** Radiographic evaluation of the angles. Osteotomy and fixation with addition wedge plate.

	Intermetatarsal		Metatarsophalangeal	
	Pre	Post	Pre	Post
12	17 <sup>th</sup>	16 <sup>th</sup>	21 <sup>st</sup>	22 <sup>nd</sup>
13	17 <sup>th</sup>	12 <sup>th</sup>	36 <sup>th</sup>	30 <sup>th</sup>
14	14 <sup>th</sup>	7 <sup>th</sup>	32 <sup>nd</sup>	21 <sup>st</sup>
15	18 <sup>th</sup>	14 <sup>th</sup>	32 <sup>nd</sup>	34 <sup>th</sup>
17	18 <sup>th</sup>	18 <sup>th</sup>	35 <sup>th</sup>	28 <sup>th</sup>
18	16 <sup>th</sup>	10 <sup>th</sup>	30 <sup>th</sup>	30 <sup>th</sup>
19	13 <sup>th</sup>	10 <sup>th</sup>	34 <sup>th</sup>	34 <sup>th</sup>
20	15 <sup>th</sup>	10 <sup>th</sup>	30 <sup>th</sup>	5 <sup>th</sup>
21	10 <sup>th</sup>	3 <sup>rd</sup>	20 <sup>th</sup>	5 <sup>th</sup>
23	18 <sup>th</sup>	12 <sup>th</sup>	20 <sup>th</sup>	18 <sup>th</sup>
24	16 <sup>th</sup>	11 <sup>th</sup>	37 <sup>th</sup>	30 <sup>th</sup>
	Means			
	15 <sup>th</sup>	11 <sup>th</sup>	29 <sup>th</sup>	23 <sup>rd</sup>

Fonte - Hospital Universitário de Taubaté - Taubaté, SP – 2009.



**Figure 7.** Percentage of satisfactory and unsatisfactory results in the feet submitted to AOP.

**Table 4.** AOFAS personal satisfaction score. Osteotomy and fixation with addition wedge plate.

	Pre	Post
12	57	60
13	52	83
14	62	95
15	34	83
17	32	40
18	29	70
19	60	73
20	20	88
21	30	82
23	34	95
24	53	83
	Means	
AOFAS	42.1	77.4

Source - Hospital Universitário de Taubaté - Taubaté, SP – 2009.

hypercorrection (hallux varus), with one foot for each complication. In the patient where hypercorrection occurred (no. 10, Table 1) we opted for surgical re-intervention, applying the inverted Chevron technique for the correction of hallux varus deformity, with a good result.

In the group submitted to AOP there were fewer complications: only one patient complained about pain above the plate. No other foot presented loosening or breakage of the screws.

The deformity reoccurred in two feet, leading to an unsatisfactory result, where both feet were operated using the AOP technique (no. of order 12 and 17, Table 4).

We did not observe superficial or deep infections or reduced mobility of the metatarsophalangeal joint in the two techniques employed.

## DISCUSSION

The treatment of symptomatic hallux valgus presents several surgical techniques, yet there is no single ideal technique for all cases. Surgical intervention almost always requires osteotomy of the first metatarsal for ray realignment. When the hallux valgus is associated with a Minus Index and varus deformity of the first ray, addition osteotomy techniques are indicated.

Just like in the literature, we found greater incidence of hallux valgus in the female patients than in the male patients, in a proportion of 9.5:1.<sup>1,3,6,7</sup> There was no significant predominance in relation to the laterality of the affected feet.

The two techniques compared in this study exhibited similar results, both in the improvement of the clinical aspects and in the pre- and postoperative radiographic parameters.

In the general sample we obtained 87.5% of satisfactory results, similar to the findings of other authors<sup>(1,4,6,9,10)</sup> In the AORE technique separately, the satisfactory results were higher, at 92.3%. On the other hand, in the AOP technique the percentage was lower, at 81.8 %, the same shown by Pappas et al.<sup>11</sup>

The mean AOFAS score in both techniques presented a significant increase, slightly higher for AORE, yet when compared, the difference was not significant, which is similar to the findings of Ruaro et al.<sup>12</sup> and Ignacio et al.<sup>13</sup> The mean AOFAS score for the AOP group presented an increase from 42.1 to 77.4 points, yet below the values obtained in the studies of Thomas et al.<sup>9</sup> and Walther et al.,<sup>14</sup> perhaps due to the fact that our casuistry is small (11 cases) and we are passing through the learning curve of the technique.

The IMA and HVA decreased in the feet operated by both techniques, even though they did not attain values of normality in the entire sample, which is the same result observed in literature.<sup>9,11-16</sup>

The proximal osteotomy of the first metatarsal promoted an improvement of the IMA in relation to the HVA where most cases, despite the decrease, did not attain levels of normality. This fact might arise from our failure to use associations with distal osteotomies in the first metatarsal or in the proximal phalanx, which would assist us in a better correction of hallux valgus deformity. The complication that appeared most important to us was hypercorrection, in a patient submitted to the AORE technique leading to a hallux varus, possibly due to excessive resection of the exostosis.

We observed delayed consolidation in only one foot submitted to the AORE technique, unlike Smith et al.,<sup>16</sup> who performed fixation with plate and screws but still observed the same complication in six feet. We did not encounter cases of absorption of the bone graft in this study.

Following in the steps of Walther et al.,<sup>14</sup> we systematically filled the space of the wedge produced by the plate with fragments of the removed exostosis.

We understand, as do several authors who perform the fixation with addition wedge plate,<sup>9,11,14-16</sup> that the advantage of this technique over AORE consists of its easy execution, as well as the fact that we are able to give the patient the all clear to start walking earlier. We believe that this is a result of the greater stability afforded by the plate in the fixation of the osteotomy, as referred to by Walther et al.<sup>14</sup>

Pain at the site of the plate was a complaint presented by one patient (4.1%), yet without the need to remove the plate, unlike other studies,<sup>11,13,15</sup> in which the plates had to be removed due to the presence of pain, breakage or loosening of the material.

## CONCLUSION

The two surgical techniques employed appeared efficacious for the treatment of hallux valgus.

The mean points of the AOFAS method in the postoperative period increased significantly in both the techniques.

The radiographic measurements of IMA and of HVA obtained a reduction in the postoperative period, statistically significant in both techniques.

The results obtained by the two surgical techniques were equivalent, with no statistical difference between them.

## REFERENCES

- Mann RA, Coughlin MJ. Adult hallux valgus. In: Mann RA, Coughlin MJ, eds. Surgery of the foot and ankle. 6th ed. St Louis: Mosby; 1993. p. 150-269.
- Carvalho AE. Hálux valgo no adulto. In: Salomão O. Clínica ortopédica: atualização em cirurgia do pé e tornozelo. Belo Horizonte: Medsi, 2001. p.365-78.
- Hardy RH, Clapham JC. Observations on hallux valgus; based on a controlled series. J Bone Joint Surg Br. 1951;33(3):376-91.
- Nery CAS. Hálux valgo. Rev Bras Ortop. 2001;36(6):183-200.
- Kaz AJ, Coughlin MJ. Crossover second toe: demographics, etiology, and radiographic assessment. Foot Ankle Int. 2007;28(12):1223-37.
- Coughlin MJ. Hallux valgus. J Bone Joint Surg Am. 1996;78(6):932-66.
- Salomão O, Carvalho Junior AE, Fernandes TD, Koyama C, Arruda JCA, Kosai T. Hálux valgo e pé plano: estudo radiográfico em 160 pacientes. Rev Bras Ortop. 1993;28(6):402-6.
- Henning EE, Hamid AJA, Silveira OL, Henning C. Estudo retrospectivo comparativo de algumas técnicas cirúrgicas no tratamento do "hallux valgus". Rev Bras Ortop. 1997;32(8):641-6.
- Thomas MG, Schroth A. Proximal MT I – Osteotomy using a titanium locking plate: midterm results of a new technique. In: 3<sup>rd</sup> Joint Meeting of International Federation of Foot And Ankle Societies, 2008. p. 115.
- Sanhudo JAV. Modificação da osteotomia em "Chevron" para correção do hálux valgo moderado a grave. Rev Bras Ortop. 2005;40(6):297-304.
- Pappas AJ, Anderson RB, Cohen BE, Davis WH, Jones CP. Comparison of opening wedge metatarsal osteotomy to proximal chevron metatarsal osteotomy for moderate to severe hallux valgus correction. In: 24<sup>th</sup> Annual Summer Meeting of American Orthopaedic Foot & Ankle Society; 2008. p. 257-8.
- Ruaro AF, Carvalho AE, Fernandes TD, Salomão O, Aguiar JAG, Meyer AT. Estudo comparativo entre duas técnicas de osteotomia no tratamento do hálux valgo: análise clínica e radiográfica Rev Bras Ortop. 2000;35(7):248-59.
- Ignácio H, Chueire AG, Carvalho Filho G, Nascimento LV, Vasconcelos UMR, Barão GTF. Estudo retrospectivo da osteotomia de base do primeiro metatarso com tratamento do hálux valgo, Acta Ortop Bras. 2006;14(1):48-52.
- Walther M, Mayer B, Dreyer F, Röser A. The proximal open wedge osteotomy with an interlocking plate for the correction of moderate to severe hallux valgus. In: 24<sup>th</sup> Annual Summer Meeting of American Orthopaedic Foot & Ankle Society, 2008. p. 268-9.
- Watson TS, Shurnas PS. Proximal metatarsal opening wedge osteotomy for the treatment of moderate to severe bunion deformities. In: 3<sup>rd</sup> Joint Meeting of International Federation of Foot And Ankle Societies, 2008. p. 49.
- Smith WB, Hyer CF, Berlet GC, DeCarbo WT, Lee TH. Opening wedge osteotomies of the proximal first metatarsal for correction of hallux valgus: a review of wedge plate fixation. In: 24<sup>th</sup> Annual Summer Meeting of American Orthopaedic Foot & Ankle Society, 2008. p. 264-5.

### Appendix 1. Hallux Valgus Evaluation Scale – AOFAS.

<b>PAIN (40 points)</b>		<b>Motion M-P (PF + DF)</b>	
None	40	normal or mild restriction (75° or more)	10
Mild, occasional	30	moderate restriction (30-74°)	5
Moderate, daily	20	severe restriction (-30°)	0
Severe, almost always present	0	<b>Motion I-P (PF)</b>	
<b>FUNCTION (45 points)</b>		no restriction	5
<b>Activity limitations</b>		severe restriction (-10°)	0
None	10	<b>Stability MP-IP (all directions)</b>	
No limitation of activities of daily living, such as work activities		Stable	5
limitation of recreational activities	7	definitely unstable or capable of dislocating	0
Limitation of ADL and recreational activities	4	<b>Callus related to MP-IP</b>	
Severe limitation of activities	0	no callus or asymptomatic callus	5
<b>Footwear</b>		symptomatic callus	0
conventional, without inserts	10	<b>Alignment (15 points)</b>	
comfortable shoe, insert	5	good, hallux well aligned	15
modified shoe or apparatus	0	fair, some degree of malalignment, no symptoms	8
		Poor, malalignment, symptomatic	0
<b>Minimum satisfactory score of 70 points</b>			